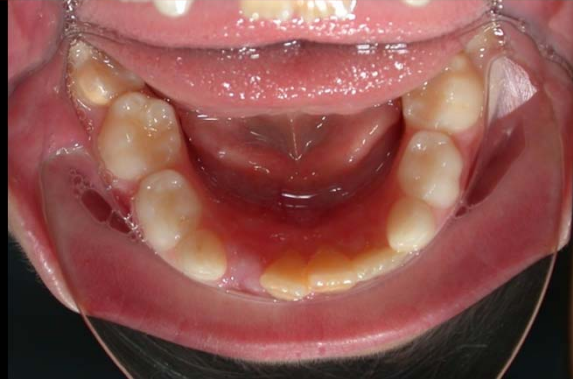
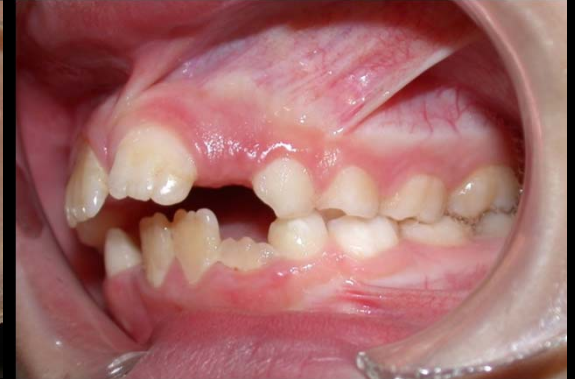
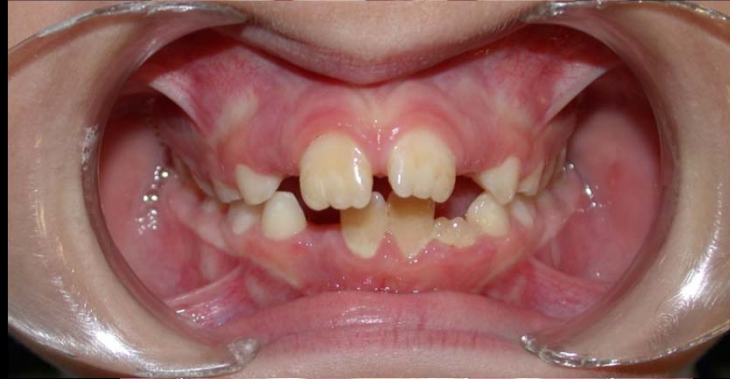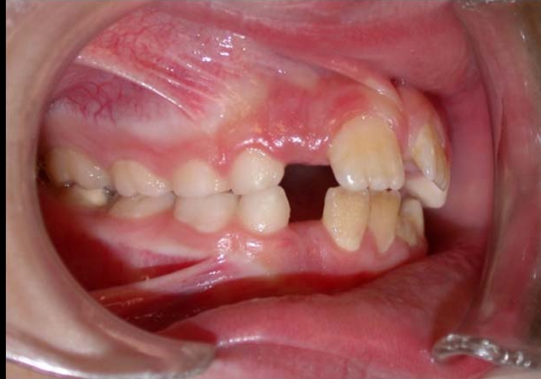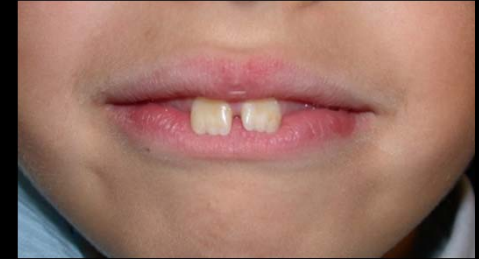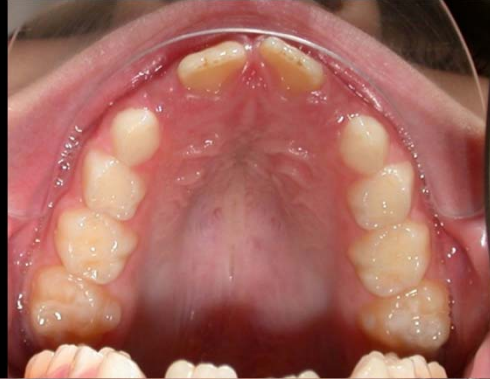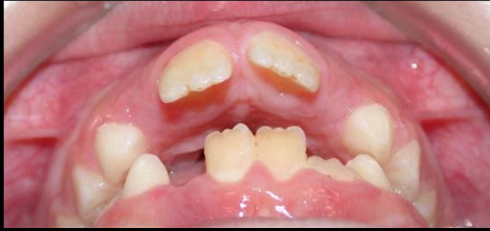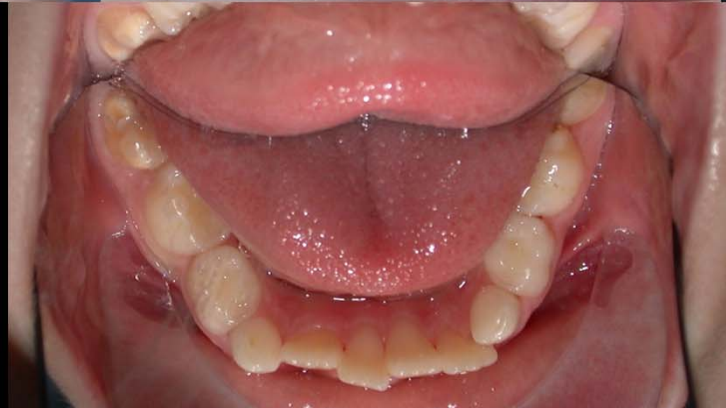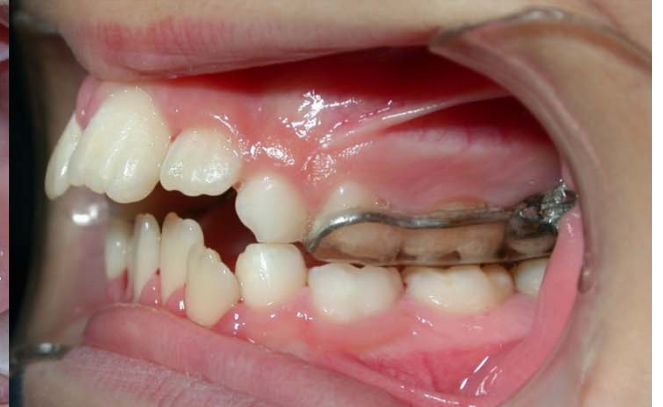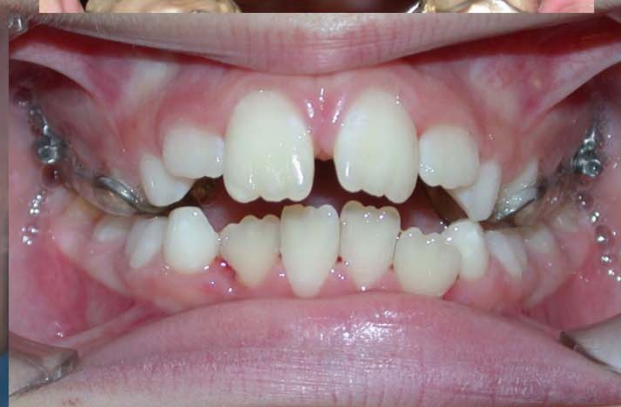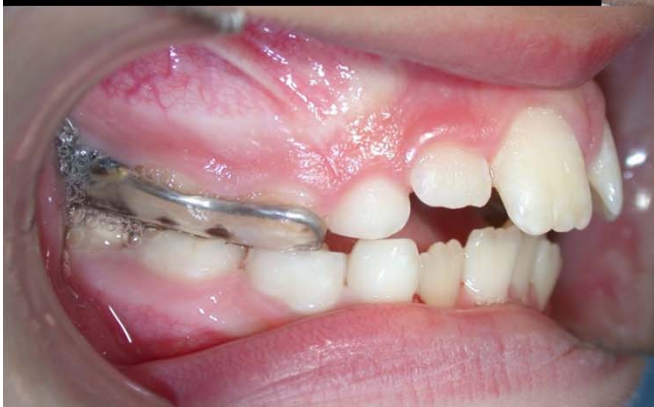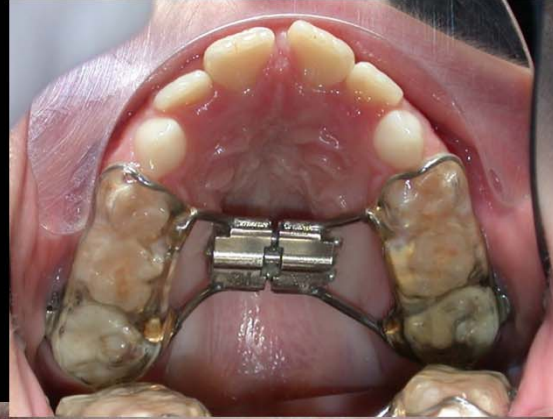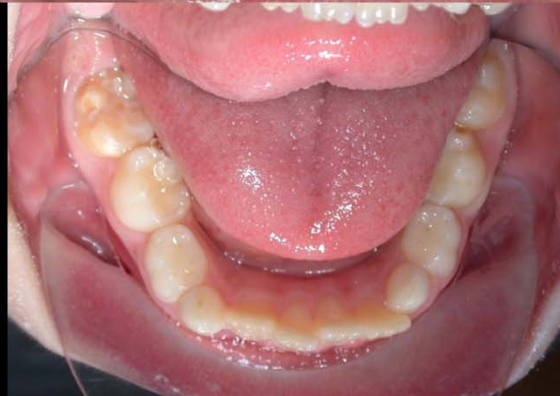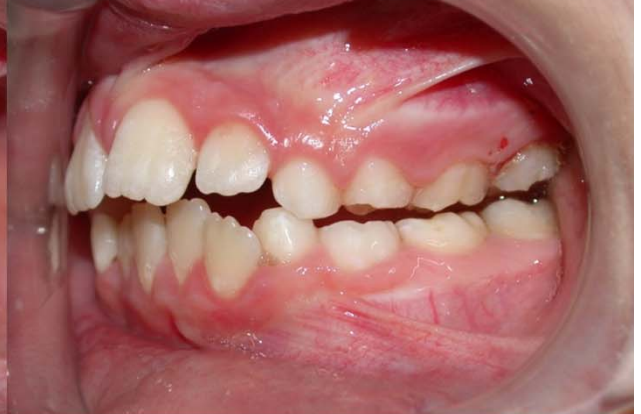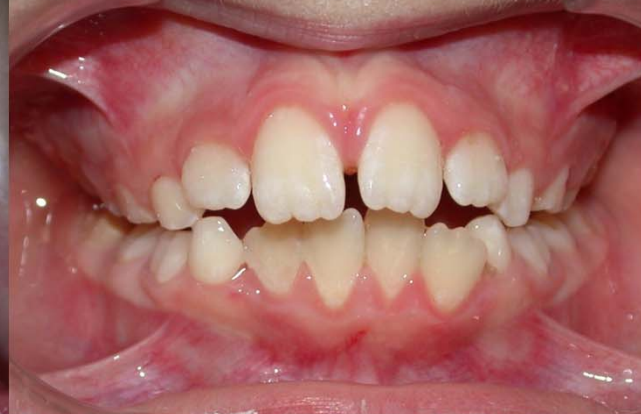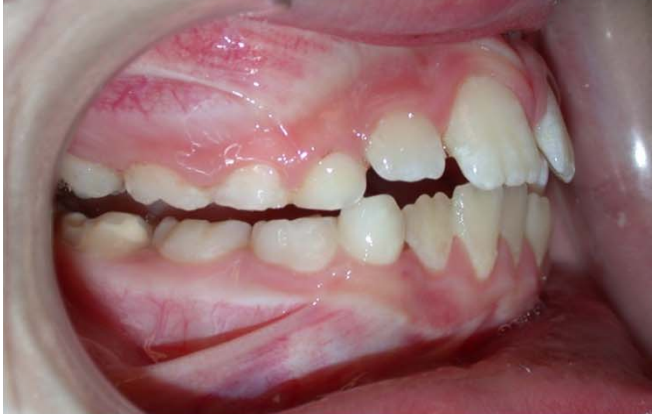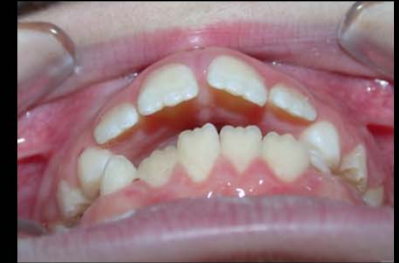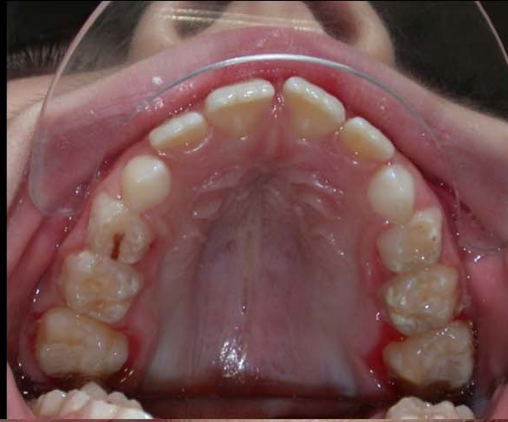
# Fotos intra-orais



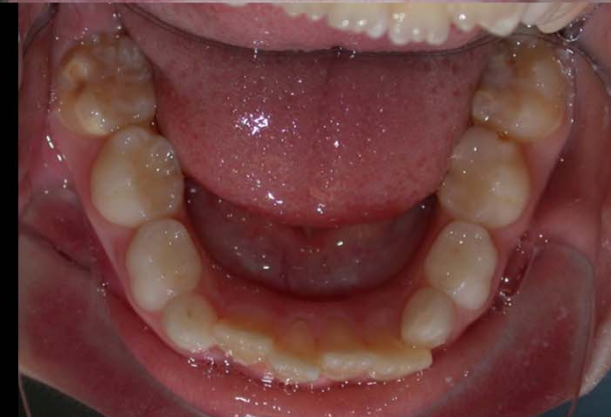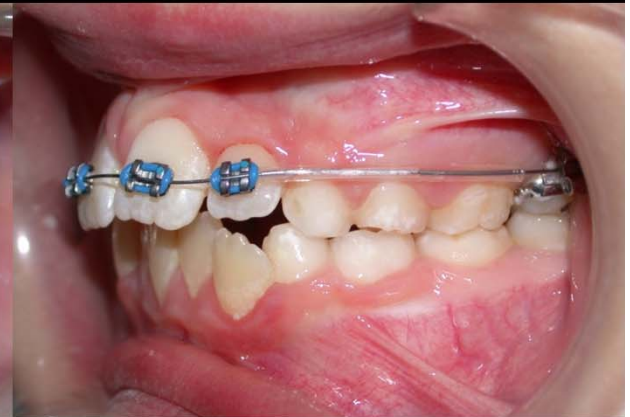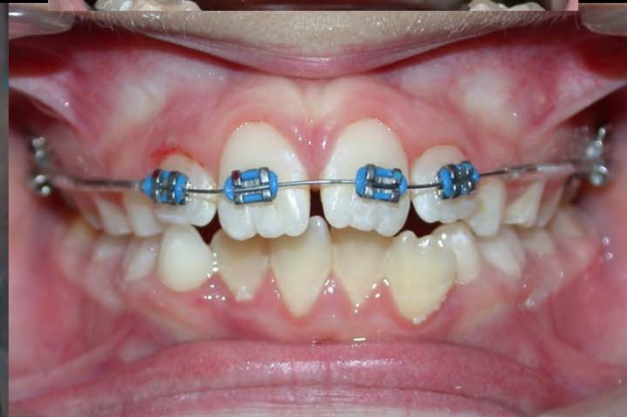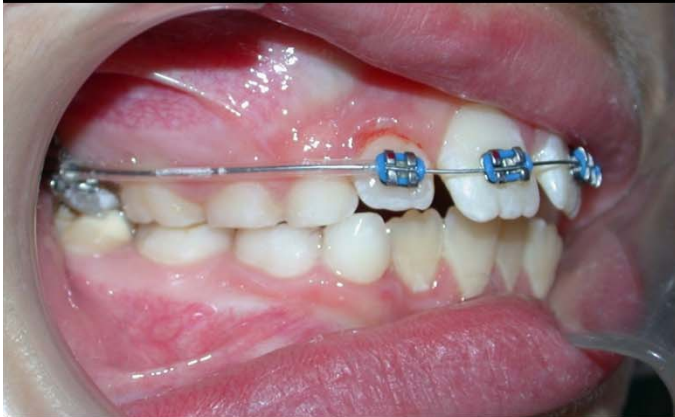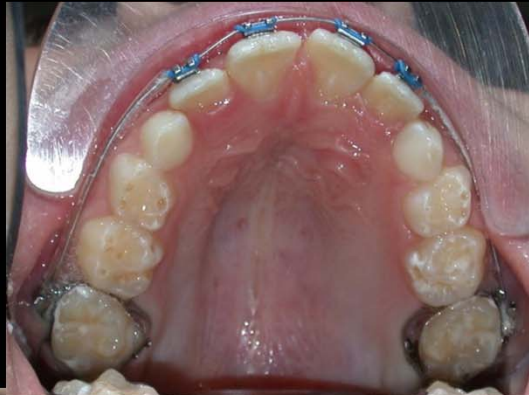# 3 meses de tratamiento



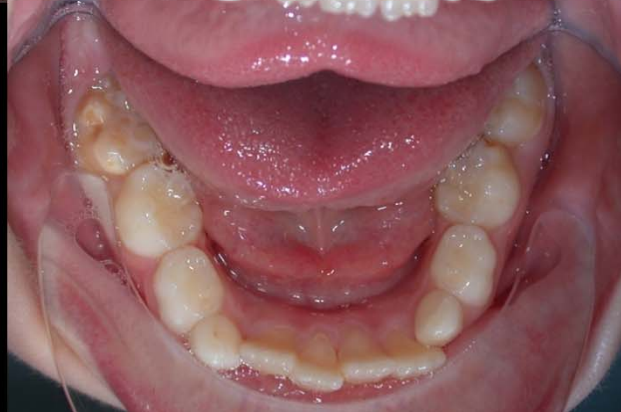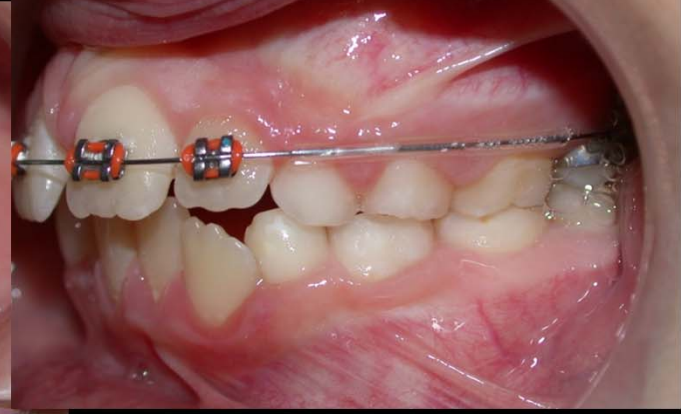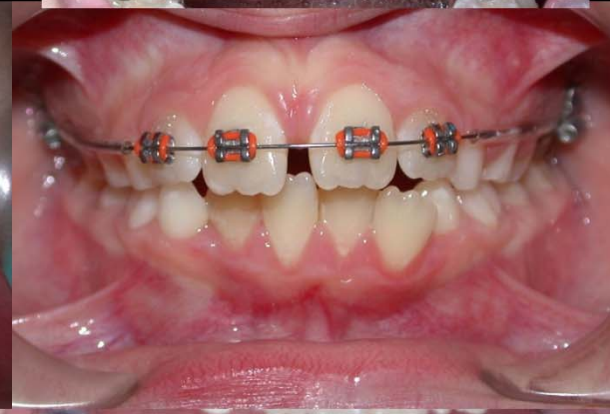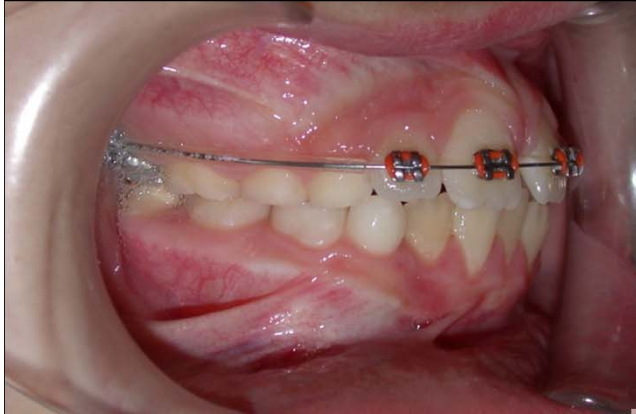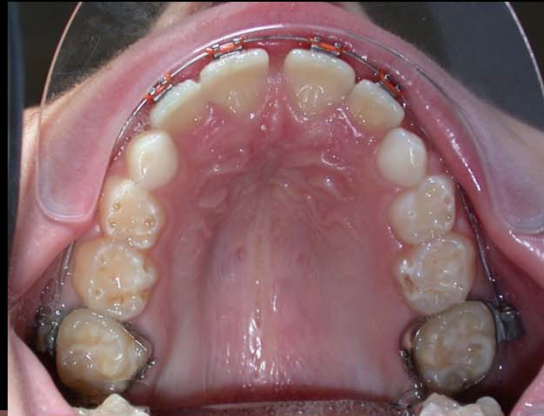# 7 meses de tratamiento



# dia da colocação de 2x4



2x4



27-12-2011

